

Combined Transfemoral and Transhepatic Embolization of Gastric Varices

BY MONI STEIN, MD, FSIR

Over the last few years, an alternative to the transjugular intrahepatic portosystemic shunt (TIPS) procedure has emerged—balloon-occluded retrograde transvenous obliteration (BRTO) of gastric varices. In this article, a new approach is described, adding the transhepatic access, which allows for blockage of the inflow veins that originate from the portal system, followed by transfemoral BRTO.

CASE PRESENTATION

A 69-year-old woman presented with bleeding large gastric varices related to portal hypertension caused by idiopathic liver cirrhosis. The patient was referred to interventional radiology, as the gastrointestinal endoscopy could not effectively sclerose or band these varices.

A CT scan was performed, which showed a large spleno-renal shunt feeding into large gastric varices (Figure 1A). As the shunt was large with voluminous flow, a concern was raised regarding the ability of BRTO alone to safely control and obliterate the varices. An additional step was taken, adding the transhepatic approach with direct access into the portal system and the feeders into the varices. Using the AccuStick™ Introducer System, access was created, and a 6-F (2-mm) vascular sheath was introduced into the splenic vein. Venography demonstrated a large, short gastric vein feeder (Figure 1B), which was cannulated with a 5-F (1.67-mm) cobra tip-shaped catheter and embolized with three 8-mm X 40-cm, two 8-mm X 20-cm, and two 6-mm X 20-cm Interlock™-35 Fibered IDC Occlusion System coils until cessation of flow (Figure 1C). An additional smaller feeder was found, the coronary vein (Figure 1D), which was embolized with two 8-mm X 20-cm and two 6-mm X 20-cm Interlock™-35 coils (Figure 1E).

Subsequently, a transfemoral approach was created, and an 8-F (2.67-mm) vascular sheath was introduced. Using a cobra tip-shaped catheter, the left renal vein was cannulated and the spleno-renal shunt was cath-

eterized using a stiff guidewire. A 8.5/11.5-mm, 6-F (2-mm) Berenstein™ occlusion balloon catheter was introduced over an Amplatz wire and was inflated with a 0.55-mL mixture of saline and contrast at 50% strength. Venography was performed, which showed reduced flow through the shunt (Figure 1F). A 10-mL mixture of contrast material, Gelfoam (Pfizer, Inc.), and 1% sodium tetradecyl sulfate was processed as a slurry in a 10-mL syringe and injected through the lumen of the occlusion balloon catheter and was left in place for 15 minutes. Through the inner lumen of the occlusion balloon, two 8-mm X 40-cm and three 8-mm X 20-cm Interlock™-35 Fibered IDC Occlusion System coils were deployed. Repeat venography demonstrated elimination of flow through the shunt (Figure 1G). In order to finalize the procedure, an additional venogram was performed through the transhepatic sheath, which demonstrated no flow into the varices (Figure 1H). Endoscopy after the BRTO procedure demonstrated complete elimination of the gastric varices.

DISCUSSION

The combined transhepatic and transfemoral BRTO approach allows for a safer and more complete bidirectional gastric variceal blockage. Both inflow and outflow veins are obliterated, trapping the varices, which allows for a more efficient and safer application of sclerosing agent. ■

Moni Stein, MD, FSIR

Chief of Interventional Radiology
Columbus Radiology
Columbus, Ohio

Disclosures: Received no compensation for this article and is not a consultant for Boston Scientific Corporation.

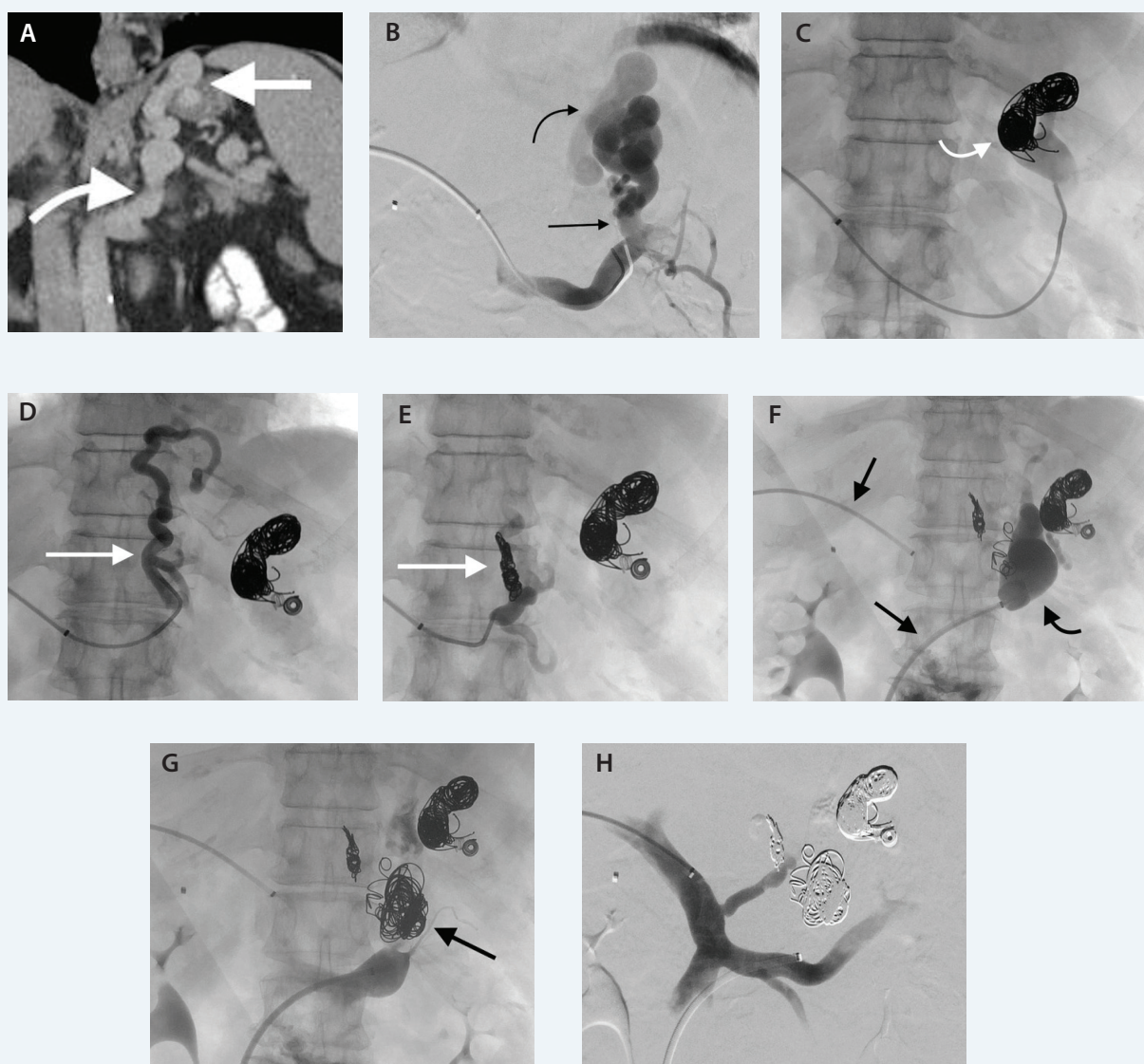


Figure 1. Coronal reconstruction of an abdominal CT scan demonstrating a large feeding coronary vein (curved arrow) into gastric varices (straight arrow) (A). Through a transhepatic approach, splenic venography shows a large, short gastric vein (straight arrow) feeding into gastric varices (curved arrow) (B). Gastric varices embolized with Interlock™-35 coils (curved arrow) until cessation of flow (C). Coronary vein feeder (straight arrow) catheterized with a cobra tip-shaped catheter (D). Coronary vein feeder embolized with Interlock™-35 coils (straight arrow) (E). The splenorenal shunt was cannulated, and venography was done through the occlusion balloon (curved arrow). The transhepatic and transfemoral sheaths are marked with straight arrows (F). Shunt embolized with Interlock™-35 coils (straight arrow) and sclerosing agent until cessation of flow (G). Concluding transhepatic portal venography demonstrates complete obliteration of gastric varices (H).